

---

---

## **Syringoma of vulva: an unusual presentation. Clinical, morphological and immunohistochemical aspects.**

*José Núñez-Troconis<sup>1,2</sup> and María Elena Vilorio de Alcarado<sup>3</sup>.*

<sup>1</sup>Department of Obstetricia and Ginecología, Manuel Noriega Trigo Hospital. Maracaibo, Venezuela.

<sup>2</sup>Facultad de Medicina, Universidad del Zulia. Maracaibo, Venezuela.

<sup>3</sup>Laboratorio de Inmunohistoquímica y Patología Molecular, Clínica D´Empaire. Maracaibo, Venezuela.

**Keywords:** syringoma, vulva, immunohistochemistry.

**Abstract.** The case of a 34-year-old woman, who consulted because she observed the appearance of numerous yellow-white asymptomatic papules on the vulva, is presented. Clinical diagnosis of syringoma of vulva was established. The pathological and immunohistochemical studies confirmed the diagnosis. Vulvar syringoma usually occurs as a multiple flesh-colored or brownish papules on both sides of *labia majora* of women in their third decade. Its diagnosis should be considered when the patient complains of vulvar pruritus and/or sweating.

### **Siringoma de vulva: una presentación inusual. Aspectos clínicos, histopatológicos e inmunohistoquímicos.**

*Invest Clin 2015; 56(1): 60 - 65*

**Palabras clave:** siringoma, vulva, inmunohistoquímica.

**Resumen.** Se presenta un caso de una paciente de 34 años de edad quien consultó por presentar la aparición de numerosas pápulas de color blanco-amarillentas en la vulva. El diagnóstico clínico de siringoma de vulva fue realizado. Los estudios de patología y de inmunohistoquímica confirmaron el diagnóstico. El siringoma vulvar usualmente se presenta como múltiples pápulas del color de la piel o marrones en ambos labios mayores en mujeres en su tercera década de la vida. Su diagnóstico debe ser considerado en pacientes que se quejan de prurito y/o sudoración vulvar.

*Recibido: 10-02-2014 Aceptado: 12-06-2014*

## INTRODUCTION

Syringoma is a benign adnexal tumor derived from intraepithelial sweat gland ducts, which occur at puberty or at midlife (1). Their occurrence is twice more common in women than men. However, further lesions can develop later in life, and reported cases range between the first and sixth decades of life (2, 3). Syringoma mainly appears on the periorbital area, especially at the lower eyelids and malar areas (1); it may also be found on the scalp, forehead, neck, anterior chest, upper abdomen and extremities (3-5). The lesions usually are bilateral and symmetrically distributed (6). Clinically, syringomas appear as small, multiple, firm, skin-colored-to-yellowish papules, 1 to 3 mm in diameter (2).

Syringoma on the genital area is a rare condition in females and males with only few vulvar cases reported in the literature to date (7). Vulvar syringoma mostly occurs in young women after puberty (8). Some patients report pruritus during the menstrual period (8).

The aim of this report was to describe the clinical, histopathological and immunohistochemical features of one case of vulvar syringoma.

## CASE

A 34-years-old woman consulted her gynecologist because she observed the appearance of numerous yellow-white asymptomatic papules on the vulva. The patient noted that the papules began to show up 10 months before. The only symptom that she reported was an increase of sweating in the external genitals.

Gynecological examination showed multiple skin-colored, discrete, asymptomatic, firm papules distributed symmetrically on the *labia majora*. The size of the lesions varied from 1 mm to 3 mm. Some papules were coalesced or grouped together forming conglomerations of 0.5 to 1 cm, involving both *labia majora* as shown in figure 1a. Also, flesh-colored and tiny papules were observed on her lower eyelids and on the front part of her neck (Figs. 1b and 1c).

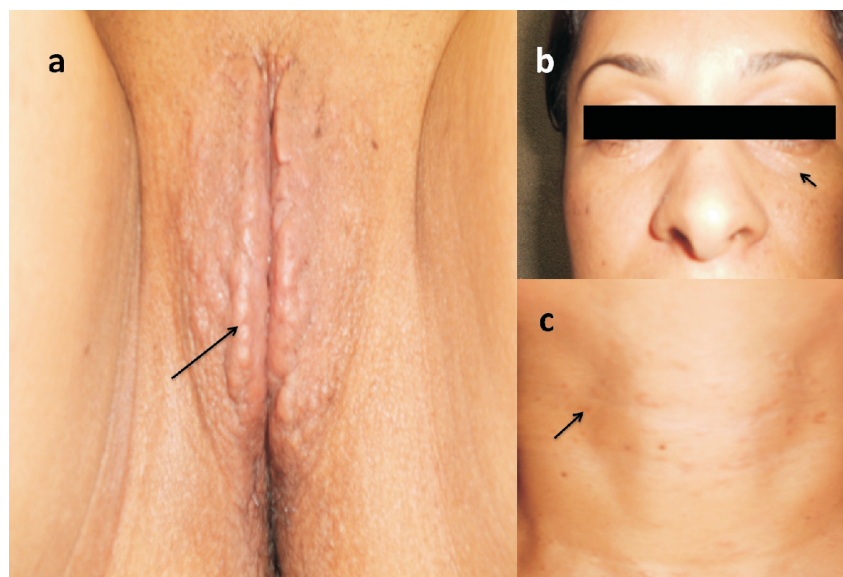


Fig. 1. a.- Vulvar syringoma: multiple papulas on *labia major*; b.- Syringoma: multiple papulas on the lower eyelids c.- Syringoma: multiples papulas on the front part of the neck. Arrows show the papules.

A skin biopsy was taken from a typical lesion or papule on the *labia majora* for histological and immunohistochemical studies.

Paraffin block obtained from the skin biopsy of the lesion on the *labia majora* was cut with a microtome. The 4 $\mu$  sections obtained were stained with haematoxylin-eosin and analyzed under a light microscope (Leica DM 100). Additional sections were cut for immunohistochemistry. Deparaffinization and rehydration of tissue sections were done with xylene and graded alcohol series, respectively. After microwave heat-pre-treatment in the high pH target retrieval solution (Dako, Denmark), slides were immersed in 0.3% H<sub>2</sub>O<sub>2</sub> for 20 minutes to block the endogenous peroxidase activity. After washing, slides were incubated for 1 hour at room temperature with monoclonal antibodies against: 1. Wide spectrum cytokeratin, clone AE1/AE3

(Dako, Denmark) at a dilution of 1:100; 2. Cytokeratin 7 (CK 7), clone OV-TL (Dako, Denmark) at a dilution of 1:50; 3. Carcino-embryonic antigen (CEA), clone II-7 (Dako, Denmark) at a dilution of 1:50; and 4. p53 protein, clone DO-7 (Dako, Denmark) at a dilution of 1:100. The two-step visualization system EnVision™ and diaminobenzidine (DAB) chromogenic (both from Dako, Denmark) were used to visualize the immunohistochemistry reaction.

Histological examination showed small sweat duct-like glandular and solid epithelial nests embedded in a fibrotic stroma in the dermis, many of them had the characteristic tadpole configuration of a syringoma (Fig. 2a). Fig. 2b showed two types of cells within the tumor or cyst small cuboidal cells, typical ductal epithelium with eccentrically located nuclei, and a distinct second population of cells with clear, vacuolated cytoplasm. Some ducts con-

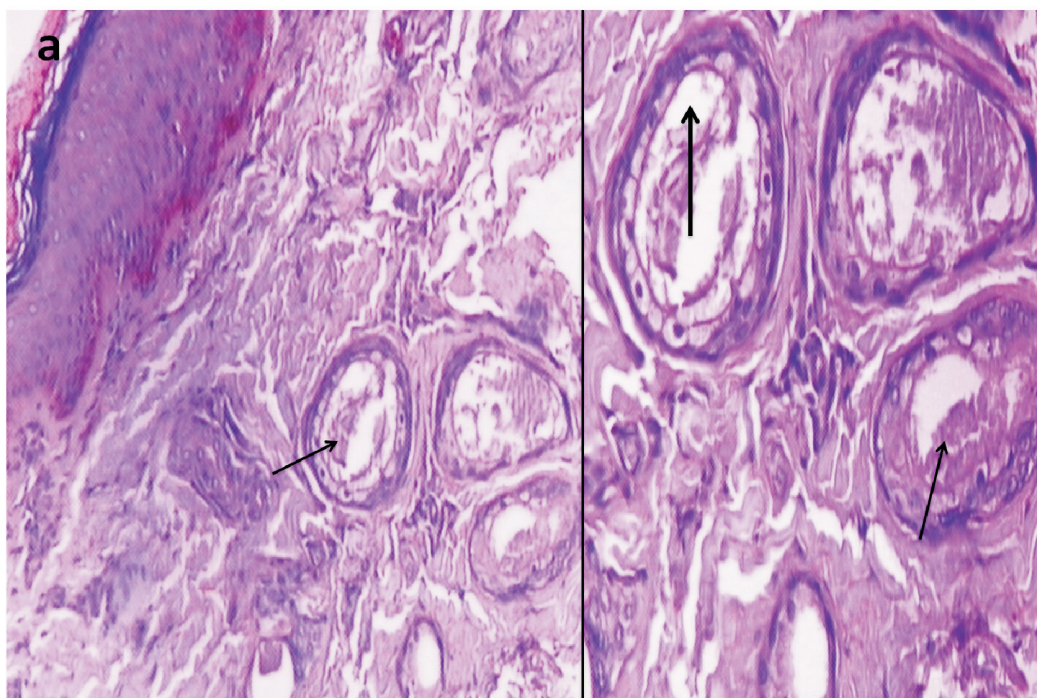


Fig. 2. a.- Tubal structures lined by rows of epithelial cells of contain colloid material in their lumina (thin arrow) and ductal structures in characteristic tadpole configuration (HE, x100); b.- Presence of many vacuolated cells in ductular portion of the tumor (thick arrow) (HE, X200).

tained amorphous secretion within the lumen. Many tumor cells had abundant periodic acid, Schiff-positive cytoplasm, suggesting accumulation of glycogen.

The immunohistochemical staining was positive to wide spectrum of antigens: cytokeratin, cytokeratin 7 and carcino-embryonic antigen (CEA) (Figs. 3a and 3b). It was negative to P53 staining as it shows in Fig. 3c.

### DISCUSSION

Syringoma was first described by Kaposi and Biesiadeki in 1874 as Lymphangioma Tuberosum Multiplex (9). As it was mentioned previously, the syringoma is a benign adnexal tumor derived from the intraepithelial eccrine duct. It may present as single or multiple papules, predominantly in women at puberty or later in life, commonly involving

the face, especially the eyelids, in 0.6% of the population (1). There is an increased frequency of this tumor among oriental females, patients with Down's Syndrome and diabetes mellitus, especially the clear-cell syringoma (2, 10, 11). Although there are reports in the literature describing families with a history of this disease (2, 12, 13). Syringomas are typically non-regressing and asymptomatic lesions (14). The clinical diagnosis of syringoma is confirmed by the histopathological examination of a biopsy of the lesion. Monoclonal antikeratin antibody tests, electron microscopy, and immunohistochemical tests confirmed the intra-epidermal eccrine gland nature of this disease (2, 12).

The first vulvar syringoma was reported by Carneiro *et al* in 1972(15). Vulvar syringoma is mainly found in women during their reproductive years, less common during adolescence and very rare in elder pa-

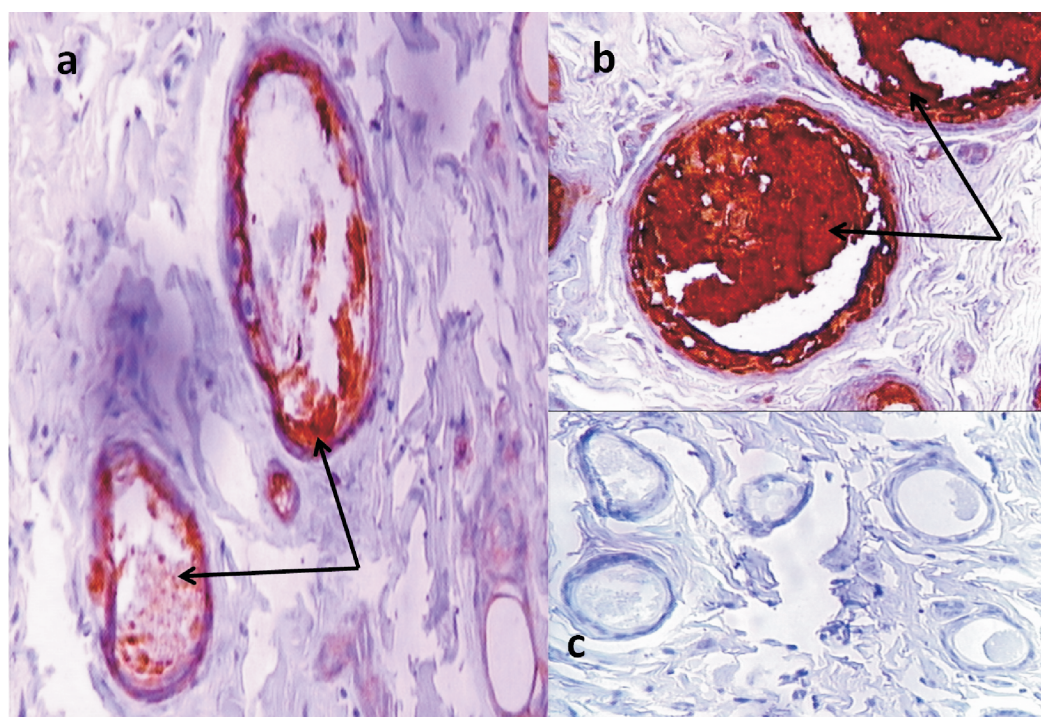


Fig. 3. a.- Immunohistochemical staining for Cytokeratin 7 positive(200X- arrow); b.- Immunohistochemical staining for CEA positive(200X-arrow); c.- Immunohistochemical staining for P53 negative(200X).

tients, up to the sixth decade (2, 8, 16, 17). Huang *et al.* (8) believe that vulvar syringoma is not very rare and may be underreported; since it is not recognized by patients and clinicians (2, 16). Because vulvar syringoma has been described in association with extragenital lesions, examination of the rest of the body, especially the eyelids and malar areas, is necessary when a suspected vulvar syringoma is found. Likewise, examination of the vulvar area is mandatory when a syringoma is found outside the genital area (2, 8).

Commonly, vulvar syringoma is asymptomatic. However, they can produce vulvar pruritus (18, 19). Huang *et al.* (8) reported vulvar pruritus in 72% of their cases, seven cases experienced aggravated pruritus during the summer time or during the menstrual period. This case did not have any difference with other reported cases in the literature except that our patient did not have vulvar pruritus, but she mentioned to have increased sweating in the vulvar area.

The clinical differential diagnosis for vulvar syringoma is broad and should exclude such diseases as epidermal cyst, steatocystoma multiplex, lymphangioma circumscriptum, chronic lichen simplex, angiokeratoma in Fox-Fordyce disease, senile angioma, condyloma acuminatum, candidiasis, scabies, pediculosis, allergic and irritant contact dermatitis, psoriasis and lichen sclerosus et atrophicus (2, 7, 8, 19-21).

It has been hypothesized that the growth of the syringoma is under hormonal influence, based on observations that they increase in size during pregnancy, menstrual period, use of oral contraceptives, and during puberty (22). However, the reports are controversial. Wallace and Smoller (22) demonstrated the positive staining of progesterone receptor (PR) expression in eight of nine cases of extragenital syringoma. Huang *et al.* (8) did

not find positive staining of PR and estrogen receptor (ER) expression in syringoma and peripheral vulvar tissue. Also Tarver *et al.* (23) did not detect ER nor PR on the vulvar syringoma. These results suggested that the syringoma was not under estrogen or progesterone control or regulated by them (8). The immunohistochemical study in this case, using markers of sweat gland tumors, such as CK7 and CEA showed the same result than in previous reports (24, 25).

There are few cases of vulvar syringoma reported in Latin-American (21, 26, 27). As far as we know, after we reviewed and investigated the literature, this is the first case ever reported in Venezuela.

Treatment of syringoma may not be necessary, but when they are symptomatic, surgery is the preferred method (17), and it is often performed on visible areas of the body for cosmetic reasons (2). Surgical methods of treating vulvar syringoma include local excision, cryotherapy, electrosurgery and carbon dioxide laser therapy. Medical therapy is unsuccessful. Therapies with steroids did not improve syringoma (2, 22).

In conclusion, vulvar syringoma usually occurs as a multiple flesh-colored or brownish papules on both sides of *labia majora* of women in their third decade, it is not rare and it is usually underreported. Its diagnosis should be considered when the patient complains of vulvar pruritus and sweating.

## REFERENCES

1. Elder D, Elenitsas R, Ragsdale BD. Tumors of the epidermal appendages. In Elder D, Elenitsas R, Jaworsky C, Johnson B Jr, editors. *Lever's histopathology of the skin*. Philadelphia: Lippincott-Raven; 1997, p: 778-779.
2. Miranda JJ, Shahabi S, Salih S, Bahtiyar OM. Vulvar syringoma, report of a case and review of the literature. *Yale J Bio Med* 2002; 207-210.

3. **Van Den Boek H, Lundquist CD.** Syringomas of the upper extremities with the onset in the sixty decade. *J Am Acad Dermatol* 1982; 6:534-536.
4. **Shelley WB, Wood MG.** Occult syringomas of scalp associated with progressive hair loss. *Arch Dermatol* 1980; 116:843-844.
5. **Tagami H, Inoue F, Yamada M, Egami K.** Syringoma of the forehead. *Int J Dermatol* 1983; 22:113-114.
6. **Thomas J, Majmudar B, Gorelkin L.** Syringoma localized to the vulva. *Arch Dermatol* 1979; 115:95-96.
7. **Dereli T, Turk BG, Kazandi AC.** Syringomas of the vulva. *Int J Gynaecol Obstet* 2007; 99(1):65-66.
8. **Huang YH, Chuang YH, Kuo T, Yang LCH, Hong HS.** Vulvar syringoma: A clinicopathological and immunohistologic study of 18 patients and results of treatment. *J Am Acad Dermatol* 2003; 48(5):735-739.
9. **Kaposi M.** Hebra diseases of the skin. *Lymphangioma tuberosum multiplex*. London. The New Syndedham Society. 1874: 3:386.
10. **Schepis C, Siragusa M, Palazzo R, Ragusa RM, Masi G, Fabrizi G.** Palpebral syringomas and Down's syndrome. *Dermatology* 1994; 189:248-250.
11. **Furue A, Hori Y, Nakabayashi Y.** Clear-cell syringoma. Association with diabetes mellitus. *Am J Dermatopathol* 1984; 6: 131-138.
12. **Hasimoto K, Gross BG, Lever WF.** Syringoma: histochemical and electron microscopy studies. *J Invest Dermatol* 1966; 46:150-166.
13. **Young AW, Herman EW, Tovell HM.** Syringoma of the vulva: incidence, diagnosis and cause of pruritus. *Obstet Gynecol* 1980; 55(4):515-518.
14. **Ghatt HJ, Proia AD, Tsoy EA.** Malignant syringoma of the eyelid. *Ophthalmology* 1984; 91:987-989.
15. **Carneiro SJ, Gardner HL, Knox JM.** Syringoma: three cases with vulvar involvement. *Obstet Gynecol* 1972; 39:95-99.
16. **Tay YK, Tham SN, Teo R.** Localized vulvar syringoma-an unusual cause of prurite vulvae. *Dermatology* 1996; 92:62-63.
17. **Spitzer M.** Home study course: Winter 2008. *J Low Genital Tract Dis* 2008; 12(1):59-61.
18. **Pérez- Bustillos A, Ruiz-González I, Delgado S, Alonso T, Ingelmo J.** Siringomas Vulvares: una causa infrecuente de prurito vulvar. *Actas Dermosifiliorg* 2008; 99: 580-581.
19. **Vilavella M, Bassas-Vila J, Pérez-Ochoa J.** Siringomas en la vulva: una causa de prurito vulvar persistente. *Piel (Bare)* 2012; Doi:10.1016/j.piel.2011.11.016.
20. **Lee JH, Chang JY, Lee KH.** Syringoma: a clinicopathologic and immunohistologic study and results of treatment. *Yonsei Med J* 2007; 48:35-40.
21. **Tapia O, Kam S, San Martin R.** Siringoma vulvar: reporte de un caso y revisión de la literatura. *Int J Morphol* 2012; 30(3):924-926.
22. **Wallace ML, Smoller BR.** Progesterone receptor positivity supports hormonal control of syringomas. *J Cutan Pathol* 1995; 22:442-445.
23. **Träger JD, Silvers J, Reed JA, Scott RA.** Neck and vulvar papules in an 8 year-old girl. *Arch Dermot* 1999; 135:203-206.
24. **Demirkesen C, Hoede N, Moll R.** Epithelial markers and differentiation in adnexal neoplasms of the skin: an immunohistochemical study including individual cytokeratins. *J Cutan Pathol* 1995; 22(6): 518-535.
25. **Kim BC, Park EJ, Kwon IH, Cho HJ, Park HR, Kim KH, Kim KJ.** An immunohistochemical study of the origin of the solid strand in syringom, using carcino-rmbryonic antigen, epithelial membrane antigen, and cytokeratin 5. *Int J Deramtol* 2012; 51(7):817-822.
26. **Ramos C, Quijano E, Carayhua D, Jiménez H, Rivera A.** Siringomas vulvar y palpebral en madre e hija. *Dermatol Peru* 2011; 21(2):76-78.
27. **Martínez Luna E, Rebollo Domínguez N, Vegas Memije ME, Arenas R.** Siringomas vulvares: informe de 2 casos. *Ginecol Obstet Mex* 2006; 74:273-276.