

ANTI-*Leishmania* EFFECT OF INTRALESIONAL PROCAÍNE AND DIBUCAÍNE IN HAMSTERS

Efecto anti-*Leishmania* de la procaina y la Dibucaina Intralesional en Hamsters

Dalmiro José Cazorla Perfetti¹, José Yancarlos Yépez Hurtado¹, Néstor Añez Reverof², Auristela Sánchez de Mirt¹ y María Eugenia Acosta Quintero¹

¹Laboratorio de Entomología Médica, UNIMETROPA, Centro de Investigaciones Biomédicas, Universidad Nacional Experimental "Francisco de Miranda", Apdo. 7403, Coro 4101, Estado Falcón, Venezuela. E-mail: Lutzomyia@hotmail.com. ²Investigaciones Parasitológicas "J.F. Torrealba", Departamento de Biología, Facultad de Ciencias, Universidad de Los Andes, Mérida, Estado Mérida, Venezuela

ABSTRACT

The effect of intralesional treatment (IL) with Procaine and Dibucaine was compared with standard dosages of Glucantime[®] administered intramuscularly (IM) to attain clinical and parasitological cures in skin lesions in outbred male hamsters infected with *Leishmania (Viannia) braziliensis*. Results revealed that all drugs tested reduced significantly ($P < 0.01$) average lesion sizes in experimental animals when compared with those untreated. Local treatment with dibucaine was as clinically efficient as systemic Glucantime[®], and more successful for clinical resolution than with procaine. Viable amastigotes were detected in nodules and/or scars in 100% of the evaluated hamsters 75-165 days after the end of the treatment ended, using smears, conventional histopathology, culture in NNN medium and the indirect immunoperoxidase method, suggesting that measurement of lesion sizes is not a valid criterion for evaluating the chemotherapeutic efficiency in experimental CL. The therapeutic clinic effectiveness of local anesthetics appeared to be associated with their half-life times as well as their lipid solubility. Preliminarily, these results appeared to support the inclusion of "cainic" local anesthetics as part of the alternative *armamentarium* in the treatment of animal and human cutaneous leishmaniasis (CL).

Key words: *Leishmania (Viannia) braziliensis*, cutaneous leishmaniasis, hamster, procaine, dibucaine.

RESUMEN

Se compara el efecto terapéutico de los anestésicos locales "cáinicos" Procaina y Dibucaína administrados intralesionalmente (IL), con el del tratamiento intramuscular (IM) convencional con Glucantime[®], para lograr la cura clínica y parasitológica sobre lesiones dérmicas en la base de la cola de hámsters machos heterocigotos experimentalmente infectados con 4×10^3 amastigotes de *Leishmania (Viannia) braziliensis*. Los resultados revelaron que todas las drogas ensayadas reducen significativamente ($P < 0,01$) los tamaños promedio de las lesiones granulomatosas, cuando se comparan con los animales controles sin tratamiento. El tratamiento local con la Dibucaína fue tan eficaz clínicamente como el Glucantime[®] administrado sistémicamente, y tuvo mejor eficacia para la resolución clínica de las lesiones que la Procaina IL. Se detectó la presencia de amastigotes viables en nódulos granulomatosos o cicatrices en la totalidad de los hámsters evaluados, después de 75-165 días de haberse finalizado los tratamientos, mediante los métodos de frotis directo, histopatología convencional, medios de cultivo (NNN) y la técnica de la inmunoperoxidasa, lo que sugiere que la medición de las lesiones cutáneas por sí solo no es un método totalmente confiable y válido para evaluar la eficacia quimioterapéutica en la LC experimental. La eficiencia clínica de los anestésicos locales parece estar relacionada con sus tiempos de vida media y lipofilia relativa. De una manera preliminar, estos resultados parecieran apoyar la inclusión de los anestésicos locales "cáinicos" como parte del *armamentarium* alternativo para el tratamiento de las LC animal y humana.

Palabras clave: *Leishmania (Viannia) braziliensis*, leishmaniasis cutánea, hámster, procaina, dibucaína.

INTRODUCTION

Cutaneous leishmaniasis (CL) is currently a world wide spread parasitic disease [32]. The current therapy schedule of CL is based mainly on pentavalent antimonial (Sb^V) compounds, such as meglumine antimoniate solution (Glucantime[®]) and sodium stibogluconate (Pentostam[®]) [33]. Despite those are successfully applied drugs, the treatment of CL still is far from ideal being considered [11, 33]. In fact, many patients could exhibit arthralgia, renal, heart, liver and pancreas disorder, depending upon dosage, drug batching and race [3, 5, 33]. In addition, antimonials are expensive and of difficult administration, especially when administered intramuscularly (IM) for long term [8]. In those cases of first line treatment failure, alternative drugs such as pentamidine and amphotericin B among others, are used [5, 21]. Nevertheless, these chemotherapeutic agents could also exhibit similar side effects as those of Sb^V [23].

As an attempt to reduce the need of large amounts of parenterally antimonials, the World Health Organization [33] recommended intralesional treatment (IL) of CL, especially with Sb, being already applied successfully by several authors [13, 17, 28]. Of interest has been the use by Yépez and Scorza [34], in Venezuelan patients of a chemotherapeutic scheme based upon local injections of Glucantime[®], its mixture with 1% lidocaine or the local anesthetic alone. This therapeutic scheme resulted in clinical resolution levels between 98 to 100%. In subsequent works, Yépez *et al.* [35] and Bendezú [2], have settled experimental basis *in vivo* and *in vitro*, respectively, confirming efficacy of lidocaine on *Leishmania* parasites. In fact, in the first cited work, Yépez *et al.* [35], the authors found that this local anesthetic reduced significantly the average lesion size in hamsters experimentally infected with *L. (V.) braziliensis*, when compared to the untreated group. In addition, Bendezú [2] using promastigotes and amastigotes cultures of *L. (L.) mexicana* and *L. (V.) braziliensis* reported leishmanicidal action doses-dependent with this "cainic" anesthetic.

Due to successfully trials carried out with application of IL lidocaine, it was proposed assaying locally other two "cainic" local anesthetics, procaine and dibucaine with lower and higher lipophilic activities than lidocaine, respectively, as an attempt to compare their leishmanicidal action to attain clinical and parasitological cure with that of Glucantime[®] IM in cutaneous lesions experimentally produced in male hamsters by inoculation with *L. (V.) braziliensis*.

MATERIALS AND METHODS

Parasites

Leishmania (Viannia) braziliensis MHOM/V/82/ZC. This strain was isolated from human case of CL at Trujillo city, Trujillo state, Venezuela, and has been maintained by continuous passages in male hamsters. It's identification was made with

monoclonal antibodies and enzyme electrophoresis by Dr. N. Saravia at CIDEIM, Cali, Colombia.

Animals and experimental infections

Outbred male hamsters, 8 to 12 weeks old, weighing ca. 100 – 120 g were inoculated subcutaneously in the base of the tail with 0.1 mL 0.85 saline containing 4×10^3 amastigotes, which were obtained from hind pad lesions of outbred male hamsters.

Drugs

N-methyl glucamine antimoniate (Glucantime[®], *Specia*) was manufactured by Rhone Poulenc, France, and 1% procaine (hydrochloride form) by Rincon Laboratories, Venezuela. 3% dibucaine (hydrochloride form) was prepared and kindly supplied by Faculty of Pharmacy, University of Los Andes, Venezuela.

Protocol for drug therapy

Chemotherapeutical trials were assayed in hamsters infected with *L. (V.) braziliensis*, with intralesional (IL) injections of procaine and dibucaine and comparing their therapeutic activities with lesions and amastigotes of a group of hamsters intramuscularly (IM) injected with Glucantime[®] (standard or positive control), and another one with no treatment (untreated or negative control). In all trials, initiation of treatment schedules took place at about two months after inoculation when leishmanial nodules exhibited sizes (diameters) of 6-8 mm. The control group (13 non treated hamsters) received daily IM injections of sterile 0.85 saline for 80 days; the systemic or standard group (N= 13) was treated with daily IM injection of 80 mg/Kg of Glucantime[®] for 20 days, in maximum of 4 series, 10 days rest between series. Two other groups of 14 animals each one had local treatment with weekly intralesional infiltrations for 7 weeks, receiving 8 mg/Kg of procaine and dibucaine, respectively.

Evaluation of treatments

After the first drug infiltration, the clinical evaluation of treatments was monitored weekly, during 24 weeks, by following the development of diameter of dermal lesions with a caliper. Two animals of each experimental group were randomly selected 75-195 days after cessation of treatment and killed with ether to assess parasitological cure by smears, conventional histopathology, culturing and the immunoperoxidase indirect method. Peripheral blood samples and biopsies of skin lesion, liver and spleen were taken for culturing in NNN medium. At the same time, additional biopsies and smears were also taken from leishmanial skin lesions. For conventional histopathological studies and the immunoperoxidase staining, biopsied tissues were fixed in 10% formaldehyde, embedded in paraffin and stained with the giemsa-colophonium method proposed by Bray and Garhnam [4] and the methodology described by Sells and Burton [27], respectively.

Statistical analysis

Kruskal-Wallis one way analysis of variance and multiple comparison tests were used to determine the significance of the results.

RESULTS AND DISCUSSION

Outbred male hamsters inoculated in the base of the tail with 4×10^3 amastigotes of *L. (V.) braziliensis* developed palpable nodules at about 30-60 days post-inoculation. No spontaneous healing or recovery from infection was observed in any animals. In untreated hamsters, lesion grew progressively to reach maximum average diameters ($\bar{X} = 28.6 \text{ mm} \pm 8.2$) at 16 weeks of clinical evaluation (FIG. 1), producing from 15-20 weeks post-infection, detecting viable amastigotes in granulomatous dermal lesions, TABLES I and II.

Hamsters parenterally treated with Glucantime[®] showed a rapid decrease in average lesion diameters (FIG. 1). This decrease persisted for up to 18 weeks, with a maximum mean lesion diameter of $6.7 \text{ mm} \pm 2.9$. After treatment was stopped, lesions slowly increased again although averaging only reached up to $8.8 \text{ mm} \pm 7.6$ at the end of the measuring period, with 3 hamsters clinically cured. Statistical significance ($P < 0.001$) was obtained when evolution of mean lesion diameters between antimonial systemic regimen and non-treated animals were compared. 75 days after cessation of treatment, parasitological evaluation of two hamsters clinically cured with Sb^V systemic regimen revealed viable amastigotes in their scar lesions, as shown in TABLES I and II.

During and after the procaine infiltration (7 and 17 weeks, respectively), mean lesion diameters were significantly inhibited when compared with those non-treated hamsters ($P < 0.01$) (FIG. 1). Nevertheless, lesion size average increased progressively, no healing clinically any animal and dying 3 of them since 13 weeks post-treatment. At the end of period of clinical observations, lesion diameters reached average of $20.1 \text{ mm} \pm 4.4$. Statistical comparison between procaine treatment and systemic antimonial regimen, revealed significance differences ($P < 0.01$), suggesting that Sb^V schedule was more efficient in clinical improvement than anesthetic regimen. Parasitological studies revealed that two animals evaluated 165 days post-treatment, both had viable amastigotes in granulomatous dermal lesions, as indicated in TABLES I and II.

As shown in FIG. 1, after the first local infiltration, mean lesion diameters were strikingly inhibited by dibucaine regimen, reaching averages between 2.8 mm and 5.6 mm during 6 months of clinical evaluation. 9 animals showed complete healing of their dermal lesions. Statistical comparison of mean lesion diameters between dibucaine treatment and non-treated hamsters revealed significant differences ($P < 0.01$). When the anesthetic regimen and the systemic antimonial treatment were compared, statistical analysis showed no significant dif-

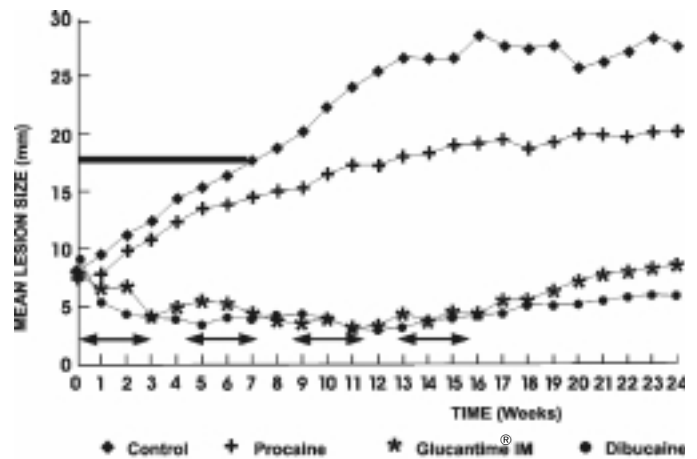


FIGURE 1. EFFECT OF TREATMENT WITH PROCAINE AND DIBUCAINE IL AND SYSTEMIC GLUCANTIME[®] ON THE DEVELOPMENT OF LESIONS IN THE BASE OF THE TAIL OF OUTBRED MALE HAMSTERS INOCULATED WITH 4×10^3 AMASTIGOTES OF *Leishmania (V.) braziliensis*. BAR INDICATES LOCAL ANESTHETICS ADMINISTRATION TIME. ARROWS INDICATE ANTIMONIAL ADMINISTRATION TIME.

ferences ($P > 0.05$) in reducing lesion diameters, suggesting that dibucaine treatment was as clinically efficient as the antimonial regimen. In addition, statistical comparison between both anesthetic schedules revealed that IL dibucaine was more efficient than procaine treatment for reducing lesion sizes ($P < 0.01$). Parasitological evaluation 141 days post treatment of two hamsters clinically cured, showed viable amastigotes in their scar lesions (TABLES I and II).

It's a well documented fact that local anesthetics have antibactericidal [1, 19] and antimicrobial activity [25]. Regarding the leishmaniasis, before and after Yépez and Scorza [34] implemented clinical use of lidocaine for the chemotherapeutical treatment of CL, several workers have used it so far as a "placebo", thus contributing to a lack of recognition of its anti-*Leishmania* action [9, 22, 31]. The experimental results reported in this paper, are a strong confirmation of part the clinical findings previously reported by Yépez and Scorza [34], as of the experimental ones *in vivo* of Yépez *et al.* [35] and *in vitro* of Bendezu [2], after demonstrating that 7 weekly intralesional injections (8 mg/Kg) of the "cainic" local anesthetics procaine and dibucaine significantly reduced the mean lesion diameters of the hamsters infected with *L. (V.) braziliensis* amastigotes. In the light of our knowledge, this is the first experience on the use of procaine and dibucaine in the experimental CL, and the second, in addition to lidocaine [2, 35], in the treatment of experimental and clinical CL with anesthetics tertiary amines. Nevertheless, in addition to our previous trials with lidocaine [35], the clinical effects of these drugs are differentials. In fact, administration schedule of dibucaine had better clinical effectiveness than the remaining anesthetic ones, being able to be cured 9 out of 14 hamsters studied. Although not observed statistically significant differences between procaine schedule

TABLE I
DETECTION OF *Leishmania (V.) braziliensis*
IN GRANULOMATOUS AND/OR CICATRICAL LESIONS IN THE BASE OF THE TAIL OF MALE HAMSTERS AFTER
TREATMENT WITH PROCAINE AND DIBUCAINE IL, AND GLUCANTIME® IM, BY SMEARS, CONVENTIONAL
HISTOPATHOLOGY AND THE IMMUNOPEROXIDASE METHOD

Hamsters Group	Days post-treatment	Hamsters		N° examined	
		Smears	(N° positive / Histopathology)	Immunoperoxidase	
Untreated	–	2/2	2/2		2/2
Procaine IL	165	2/2	2/2		2/2
Dibucaine IL*	141	2/2	2/2		2/2
Glucantime® IM*	75	2/2	2/2		2/2

*Hamsters clinically cured.

TABLE II
DETECTION OF *Leishmania (V.) braziliensis* BY CULTURING IN NNN MEDIA OF PERIPHERAL BLOOD AND BIOPSIES OF
CICATRICAL AND/OR GRANULOMATOUS LESIONS (THE BASE OF THE TAIL), LIVER AND SPLEEN OF MALE HAMSTERS
AFTER TREATMENT WITH PROCAINE AND DIBUCAINE IL AND GLUCANTIME® IM

Hamsters Group	Days post-treatment	Hamsters		N° examined	
		Lesion	Liver	(N° positive / Blood)	Spleen
Untreated	–	2/2	0/2	0/2	0/2
Procaine IL	165	0/2	0/2	0/2	0/2
Dibucaine IL*	141	0/2	0/2	0/2	0/2
Glucantime® IM*	75	1/2	0/2	0/2	0/2

* Hamsters clinically cured.

when was compared with that of lidocaine [34], their clinical effects regarding non-treated hamsters were significant.

The therapeutic efficiency observed with the 3 local anesthetics studied both by Yépez *et al.* [35] and in the present work, appeared to be associated with their half-life times as well as to their hydrophobicity degree or lipid solubility. In fact, this is suggested since the aminoester local anesthetics, like procaine, are known to be rapidly hydrolyzed by plasma cholinesterase [18]. By contrast, aminoamide local anesthetics such as lidocaine and dibucaine are slowly metabolized by liver microsomal enzymes, being relatively slower for dibucaine [18]. Concerning hydrophobicity (*i.e.*, lipophilic affinity), dibucaine is considerably more lipid soluble than lidocaine and procaine, which displays the lowest lipid solubility of all them, due to its strongly basic properties [18, 24, 29].

Amphiphilic molecules, such as local anesthetics, are known to be modifiers of biological membrane functions [10]. Most studies suggest that anesthetic molecules interact with membrane proteins. Nevertheless, there is a long-standing debate as to whether their effects on membranous enzymes were indirect resulting from lipid perturbation, or rather to direct interactions of anesthetics with proteins [14, 29]. In a previous work for studying the action of lidocaine on *L. (V.) braziliensis* ultrastructure [35], we have taken in to account the Tarba and Cracium [29] approach, who sustain that the Transmission Electron

Microscopy (TEM) can be used, at least qualitatively, for providing information regarding the relationships between fine structure and physiological effects of local anesthetics on cells. Thus, in such paper we speculated that the primary action site of lidocaine was located on the amastigote plasma membrane and its subpellicular microtubules, as judging by disruption and morphologic alterations detected in these structures by means of TEM. In this same sense, we have obtained similar ultrastructural results by injecting procaine and dibucaine into granulomatous dermal lesions of hamsters [6]. Therefore, one can not rule out the possibility that these structures are the main targets of the “cainic” local anesthetics assayed on leishmanial parasites. Likewise, local anesthetics might interfere with *Leishmania* mitochondrial metabolism, by inhibition of the respiration and uncoupling of oxidative phosphorylation, as has been extensively found in other cellular models [20, 29], and also appears to be supported by consistent disruption and morphologic alteration detected by us on the fine structure of leishmania kinetoplast-mitochondrion and mitochondria in hamsters [6, 35].

In spite of Ercoli and Coelho [12] and Hanson *et al.* [16] recommend measuring size of lesions as a valid criterion for evaluating anti-*Leishmania* drugs, the results obtained in the present study strongly suggest that such a criterion is far from being considered fully reliable in the hamster model, as judging by detection of viable amastigotes in 100% animals 75-165 days after treatment. These observations confirm our previous

trials [7, 35], as well as those of Travi *et al.* [30], in the *Viannia* species-hamster model, which were also detected amastigotes in scars or other tissues several days after cessation of drug application. Furthermore, similar observations have been documented by several workers in patients that showed clinical resolution of their dermal lesions, after chemotherapy or immunotherapy applications [15, 26]. These aforementioned findings have important clinic-epidemiological implications, due to those individuals, including any susceptible animals, with unsuccessfully parasitological cured scar lesions could eventually exhibit recidivans with a possible mucosal involvement and its subsequent clinical complications and increasing cost of treatment. Likewise, these patients, or animals, might be considered potentially as intradomiciliar reservoir of *Leishmania* parasites.

Encouraged by the preliminary clinical evidences with lidocaine of Yépez and Scorza [34], and based on experimental results previously reported [2, 35] and those in the present paper, we suggest the use of intralesional application of "cainic" anesthetics as potential alternative therapy in the treatment of animal and human CL, with mild effects and significantly lower costs, which is very important due to scarcity and high cost of antimonial drugs for endemically exposed populations in developing countries.

CONCLUSIONS

- Procaine and Dibucaine reduced significantly average lesion sizes in comparison with non treated hamsters.
- Dibucaine schedule was as clinically efficient as systemic antimonial regimen, and more successful than Procaine one.
- Therapeutic efficacy of local anesthetics seemed to be related with their half life times and their lipid solubility.
- Measuring lesion size appeared not to be a valid criterion for evaluating chemotherapeutic efficacy in experimental CL, as judging by finding of viable amastigotes in all evaluated animals 75-165 post-treatment.
- Local anesthetics should be considered as potential alternative drugs for the treatment of animal and human CL.

ACKNOWLEDGEMENTS

This study was supported by Decanato de Investigaciones de la Universidad Nacional Experimental "Francisco de Miranda", Coro, estado Falcón, Venezuela (Grant CTI-96-007).

BIBLIOGRAPHIC REFERENCES

- [1] AYDIN, O.; EYIGOR, M.; AYDIN, N. Antimicrobial activity of ropivacaine and other local anesthetics. **Eur. J. Anaesthesiol.** 18: 687 – 694. 2001
- [2] BENDEZÚ, H. **Evaluación *in vitro* del efecto leishmanicida del clorhidrato de lidocaína**, Núcleo Universitario Rafael Rangel, Universidad de Los Andes, Trujillo, Venezuela. (Tesis de Maestría). 57 pp. 2000.
- [3] BERMAN, J. Experimental chemotherapy- a critical review. In: **Human Parasitic Disease. Leishmaniasis**. Eds. Chang, K & Bray, R. Elsevier, Amsterdam, Holland: 111- 138 pp. 1985.
- [4] BRAY, R.; GARHNAM, P. The giemsa colophonium method for staining protozoa in tissue sections. **Indian. J. Malariol.** 16: 153. 1962.
- [5] BRYCESON, A. Therapy in man. In: **The leishmaniasis in biology and Medicine**. Eds. Peters, W & Killick-Kendrick, R. Academic Press, London, England: 847 – 907 pp. 1987.
- [6] CAZORLA, D. **Nuevos ensayos quimioterapéuticos intralesionales en leishmaniasis cutánea experimental**, Núcleo Universitario Rafael Rangel, Universidad de Los Andes, Trujillo, Venezuela. (Tesis de Maestría). 121 pp. 1985.
- [7] CAZORLA, D.; YEPEZ, J.; AÑEZ, N.; DE MIRT, A. Efecto del tratamiento intralesional con clorhidrato de emetina sobre *Leishmania (Viannia) braziliensis* en hamsters. **Invest. Clin.** 42: 5 – 21. 2001.
- [8] CONVIT, J.; CASTELLANO, P.; RONDON, A.; PINARDI, M.; URLICH, M.; CASTES, M.; BLOOM, B.; GARCIA, K. Immunotherapy versus chemotherapy in localized cutaneous leishmaniasis. **Lancet.** 21: 401 – 404. 1987.
- [9] CURRIE, M. Treatment of cutaneous leishmaniasis by curettage. **Brit. Med. J.** 287: 1105 – 1106. 1983.
- [10] DE FORESTA, B.; MERAH, Z.; LE MARIE, M.; CHAMPELL, PH. How to evaluate the distribution of an invisible amphiphile between biological membranes and water. **Anal. Biochem.** 189: 56 – 67. 1990.
- [11] DOGRA, J. Current therapies for treatment of cutaneous leishmaniasis in India. **Infection.** 20: 11 – 14. 1992.
- [12] ERCOLI, N.; COELHO, M. Problems of drug evaluation in cutaneous leishmaniasis. **Ann. Trop. Med. Parasitol.** 61: 488 – 499. 1967.
- [13] FARIS, R.; JARALLAH, J.; KHOJA, T.; AL-YAMAN, M. Intralesional treatment of cutaneous leishmaniasis with sodium stibogluconate antimony. **Inter. J. Dermatol.** 32: 610 – 612. 1993.
- [14] GARCIA-MARTIN, E.; GUTIERREZ-MERINO, C. Local anesthetics inhibit the Ca^{+2} , Mg^{+2} -ATPase activity of rat brain synaptosomes. **J. Neurochem.** 47: 668 – 672. 1986.

- [15] GUEVARA, P.; RAMIREZ, J.; ROJAS, E.; SCORZA, J.; GONZALEZ, N.; AÑEZ, N. *Leishmania braziliensis* in blood 30 years after cure. **Lancet**. 341: 1341. 1993.
- [16] HANSON, W.; CHAPMAN, W.; WAITS, V.; LOVELACE, J. Development of *Leishmania (Viannia) panamensis* lesions and relationship of numbers of amastigotes to lesion area antimony-treated and untreated hamsters. **J. Parasitol.** 77: 780 – 783. 1991.
- [17] HARMS, G.; CHEHADE, A.; DOUBA, M.; ROEPKE, M.; MOUKEN, A.; RESEMKAIMER, F.; BIENZLE, Q. A randomized trial comparing a pentavalent antimonial drug and recombinant interferon gamma in the local treatment of cutaneous leishmaniasis. **Trans. R. Soc. Trop. Med. Hyg.** 85: 214 – 216. 1991.
- [18] HONDEGHEM, L.; MILLER, R. Anestésicos locales. In: **Farmacología básica y clínica**. Ed. Karzung, B. El Manual Moderno SA de CV, DF, México: 298 – 304 pp. 1987.
- [19] HUGHES, W.; STEWART, H. Antimicrobial activity of certain local anesthetics. **The J. Phar. & Pharmacol.** 9: 431. 1957.
- [20] KUTCHAI, H.; GEDDIS, L. Inhibition of the Na,K-ATPase of canine renal medulla by several local anesthetics. **Pharmacol. Res.** 43: 399 – 403. 2001.
- [21] MARSDEN, P.; JONES, T. Clinical manifestations, diagnosis and treatment of leishmaniasis. In: **Human Parasitic Disease. Leishmaniasis**. Eds. Chang, K & Bray, R. Elsevier, Amsterdam, Holland: 183- 198 pp. 1985.
- [22] NAVIN, T.; BYRON, A.; ARANA, A.; ARANA, F.; DE MERIDA, A.; CASTILLO, L.; POZUELOS, J. Placebo controlled clinical trial of meglumine antimoniate (Glucantime®) vs. Localized controlled heat in the treatment of cutaneous leishmaniasis in Guatemala. **Am. J. Trop. Med. Hyg.** 42: 43 – 50. 1990.
- [23] OLLIARO, P.; BRYCESON, A. Practical progress and new drugs for changing patterns of leishmaniasis. **Parasitol Today**. 9: 232 – 328. 1993.
- [24] RITCHIE, J.; GREEN, N. Anestésicos locales. In: **Las Bases Farmacológicas de la Terapéutica**. Eds. Goodman, A., Goodman, L., Rall, T. & Murad, F. Médica Panamericana, Buenos Aires, Argentina: 300 – 317 pp. 1986.
- [25] RODRIGUES, A.; PINA-VAZ, C.; MARDH, P.; MARTINEZ DE OLIVEIRA, J.; FREITAS DA FONSECA, A. Inhibition of germ tube formation by *Candida albicans* by local anesthetics: an effect related to ionic channel blockade. **Curr. Microbiol.** 40: 145-148 pp. 2000.
- [26] SARAIVIA, N.; WEIGLE, K.; SEGURA, I.; HOLMES, S.; PACHECO, R.; LABRADA, L.; GONCALVES, A. Recurrent lesions in human *Leishmania braziliensis* infection-reactivation or reinfection? **Lancet**. 336: 398 – 402. 1990.
- [27] SELLS, P.; BURTON, M. Identification of *Leishmania* amastigotes and their antigens in formalin tissue by immunoperoxidase staining. **Trans. R. Soc. Trop. Med. Hyg.** 75: 461 – 468. 1981.
- [28] SHARQUIE, K.; AL-TALIB, K.; CHU, A. Intralesional therapy of cutaneous leishmaniasis with sodium stibogluconate antimony. **Brit. J. Dermatol.** 119: 53 – 57. 1988.
- [29] TARBA, C.; CRACIUM, C. A comparative study of the effects of procaine, lidocaine, tetracaine and dibucaine on the functions and ultrastructure of isolated rat liver mitochondria. **Biochim. Biophys. Acta.** 1019: 19 – 28. 1990.
- [30] TRAVI, B.; MARTINEZ J.; ZEA, A. Antimonial treatment of hamsters infected with *Leishmania (Viannia) panamensis*: assessment of parasitological cure with different therapeutic schedules. **Trans. R. Soc. Trop. Med. Hyg.** 85: 567 -569. 1993.
- [31] VELASCO-CASTREJÓN, O.; WALTON, B.; RIVAS-SÁNCHEZ, B.; GARCÍA, M.; LÁZARO, G.; HOBART, O.; ROLDÁN, S.; FLORIAN-VERDUGO, J.; MUNGUÍASALDANA, A.; BERZALUCE, R. Treatment of cutaneous leishmaniasis with localizad current field (radio frequency) in Tabasco, Mexico. **Am. J. Trop. Med. Hyg.** 57: 309 – 312. 1997.
- [32] WORLD HEALTH ORGANIZATION. **The leishmaniasis. Report of a WHO expert committee**. Tech Rep Series WHO N° 701. Geneva: WHO. 1- 141 pp. 1984.
- [33] WORLD HEALTH ORGANIZATION. **Control of the leishmaniases: Report of a WHO expert committee**. Tech Rep Series WHO N° 793. Geneva: WHO. 1- 158 pp. 1990.
- [34] YÉPEZ J.; SCORZA, J. Intralesional chemotherapy with meglumine plus lidocaine of localized cutaneous leishmaniasis in Trujillo state, Venezuela. **Bol. Dir. Malariaiol. Saneam. Amb.** 35: 71 -75. 1995.
- [35] YÉPEZ, J.; CAZORLA, D.; DE MIRT, A.; AÑEZ, N.; DE YARBUH, A. Effect of intralesionall treatment with lidocaine and Glucantime® in hamsters infected with *Leishmania (Viannia) braziliensis*. **Bol. Dir. Malariaiol. Saneam. Amb.** 39: 10-20. 1999.